Case Report

Heart Failure with Preserved Ejection Fraction of Challenging Management – Prolonged Echocardiographic Follow-Up and the Role of Multimodality Imaging

Max Koki Yonamine,[1] Nilton Jorge Aragão,[1] Vanessa Cardoso Pereira,[1] Lucyo Flávio Bezerra Diniz,[1] Fernanda Miyuki Sasaki,[1] Jemima Araújo da Silva Batista,[1] Anderson Armstrong[1]

Universidade Federal do Vale do São Francisco,[1] Petrolina, PE – Brazil

Introduction

Cardiac amyloidosis (CA) is an infiltrative disease characterized by the extracellular deposition of amyloid proteins, leading to myocardial dysfunction and heart failure with a restrictive pattern.[1] In recent years, there has been a growing clinical suspicion and increased identification of new cases, driven by advances in imaging techniques.[2] However, diagnosis remains challenging, especially in older patients with multiple comorbidities. Early recognition of CA is crucial since disease-modifying therapies may slow its progression. Tests such as myocardial scintigraphy, cardiac magnetic resonance imaging (CMR), and echocardiography play a central role in the diagnostic approach.[3]

We present the case of a complex management of CA in which the integrated use of different imaging modalities was decisive for diagnostic confirmation.

Case Report

An 83-year-old female patient with dyslipidemia began cardiology follow-up in 2016, with no specific cardiovascular complaints at the time. Her medical history included bilateral carpal tunnel syndrome, surgically treated more than 10 years prior. Initial examinations revealed an electrocardiogram (ECG) showing left anterior fascicular block (Figure 1) and an echocardiogram showing eccentric hypertrophy, left ventricular ejection fraction of 65%, impaired ventricular relaxation, borderline left atrial dimensions, and mild aortic valve disease. Initial laboratory tests showed no significant abnormalities. She reported exposure to biomass smoke (wood-burning stove), and spirometry revealed a mild obstructive ventilatory pattern.

In subsequent visits, due to episodes of chest discomfort and the onset of exertional dyspnea previously well tolerated, noninvasive risk stratification with myocardial scintigraphy was performed. The exam revealed moderate-intensity and small-extent ischemia in the inferior territory of the left ventricle, and optimized clinical treatment was initiated.

The patient remained under follow-up for atherosclerotic disease. However, despite optimized therapy and frequent monitoring, she continued to present with heart failure with preserved ejection fraction that was difficult to manage. Persistent dyspnea was at times attributed to anemia, and investigation by the Hematology team led to a diagnosis of myelodysplastic syndrome, with a conservative approach adopted.

Over time, she remained dyspneic in New York Heart Association (NYHA) functional class II-III. Despite the use of diuretics to manage hypervolemia, N-terminal pro-B-type natriuretic peptide (NT-proBNP) levels remained elevated (2116, 2027, 1059, 1242 pg/mL). She gradually developed intolerance to vasodilators, experiencing hypotensive episodes even at minimal doses, along with signs of orthostatic hypotension, which led to the progressive reduction and eventual discontinuation of these medications.

During clinical follow-up, it was noted that the progression of aortic valve disease and ECG findings were not proportional to the increase in left ventricular mass and worsening of diastolic function (Table 1). The patient was then referred to a specialized center for cardiomyopathy evaluation for suspected CA.

Serum and urine immunofixation tests were performed and returned negative for monoclonal components related to amyloid light-chain (AL) amyloidosis. CMR showed left ventricular wall hypertrophy with some degree of septal asymmetry and mid-myocardial late gadolinium enhancement (Figure 2). Bone scintigraphy with pyrophosphate showed a Perugini score of 3. Semiquantitative analysis of radiotracer uptake revealed a heart-to-contralateral hemithorax ratio of 2.05 at 1 hour and 1.89 at 3 hours (Figure 2).

The imaging findings were consistent with a diagnosis of transthyretin (TTR) amyloidosis (ATTR). Subsequent genetic testing did not identify any known mutations, confirming the diagnosis of wild-type ATTR (ATTRwt). At that point, the patient was already extremely frail, bedridden, and experiencing severe symptoms. The case was discussed with the patient and her family, and referral to the palliative care team was decided upon.

Discussion

This case illustrates the diagnostic challenges of CA and highlights the importance of early clinical suspicion. CA is primarily classified into two types: (i) AL amyloidosis,

Keywords

Cardiac Amyloidosis; Restrictive Cardiomyopathy; ATTR Amyloidosis

Mailing Address: Anderson da Costa Armstrong •
Universidade Federal do Vale do São Francisco - Av. José de Sá Maniçoba,141. Postal Code 56304-917, Centro, Petrolina, PE – Brazil
E-mail: anderson.armstrong@univasf.edu.br
Manuscript received May 15, 2025, revised manuscript July 03, 2025, accepted July 24, 2025
Editor responsible for the review: Maria Otto

DOI: https://doi.org/10.36660/abcimg.20250042i

Table 1 – Echocardiographic evolution over more than 7 years of clinical follow-up

	OCT/16	APR/18	SEP/19	MAY/20	MAY/21	NOV/21	JUN/23
AO	38	38	40	40	39	38	38
LAVI	34	40	44	53	53	55	53
IVS	10	11	12	12	11	11	13
PW	10	11	12	11	12	12	13
LVDD	50	52	49	51	52	51	53
LVMI	147.5	174.4	178.8	175.2	185.4	201.9	228.3
LVEF	65	58	64	62	58	56	62
Diastolic dysfunction	I	II	I	II	II	II	II
LAVI	34	40	44	51	53	55	53
RAVI			22.6	28.7	37.3	32.6	24
AVA	2.1	1.9	1.6	1.9	1.2	1.2	1.2
SV	56.8	56.6	61	57.5	42.3	52	47
MG	< 10	8.3	16	11	12.8	19	17
PASP	48	38	39	50	66	64	44

AO: aortic diameter; AVA: aortic valve area; LVDD: left ventricular end-diastolic diameter; LVEF: left ventricular ejection fraction; MG: mean gradient; LVMI: left ventricular mass index; PW: posterior wall; PASP: pulmonary artery systolic pressure; IVS: interventricular septum; LAVI: left atrial volume index; RAVI: right atrial volume index; SV: stroke volume.

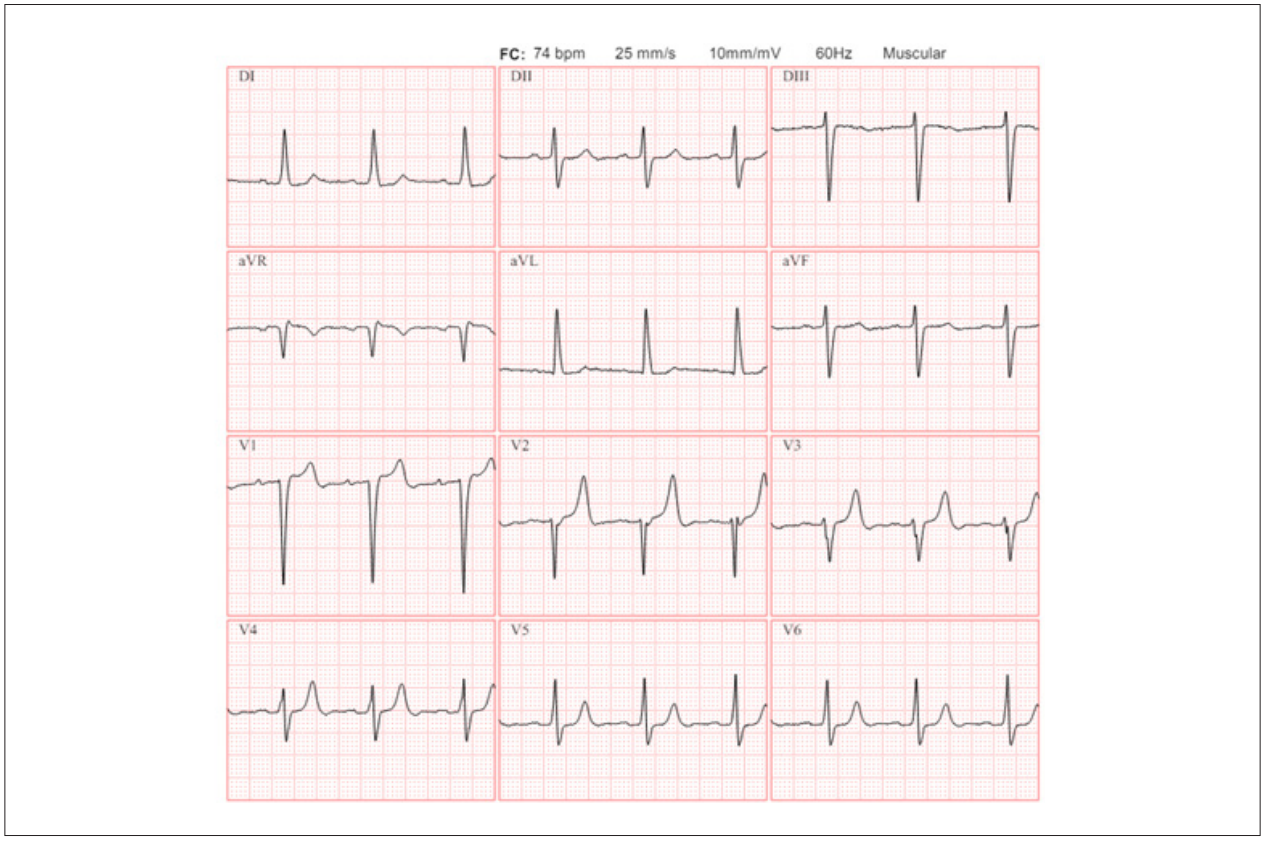

Figure 1 – *12-lead ECG showing sinus rhythm and left anterior fascicular block. ECG: electrocardiography.*

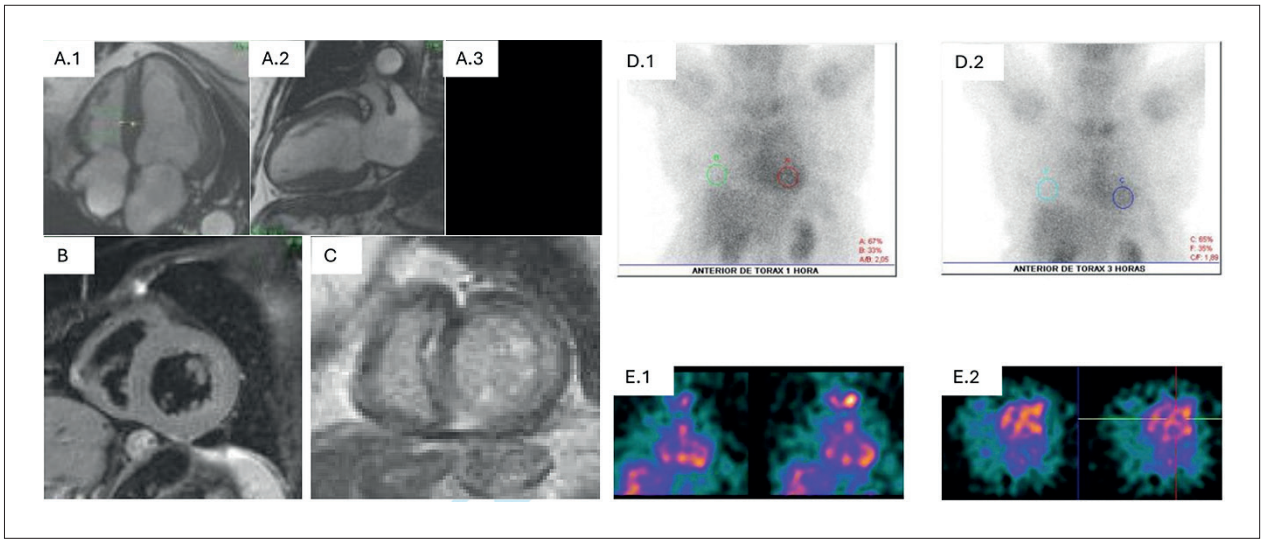

Figure 2 – *CMR and pyrophosphate myocardial scintigraphy. A) Cine images in SSFP sequence: A.1 (four-chamber view), A.2 (two-chamber view), A.3 (three-chamber view), showing increased wall thickness of the left ventricle; B) Short-axis view, T2-weighted sequence with fat saturation, showing no evidence of myocardial edema (absence of inflammatory signal); C) Short-axis view, late gadolinium enhancement sequence, demonstrating a circumferential endocardial enhancement pattern; D) Planar images from technetium pyrophosphate myocardial scintigraphy: D.1 (1-hour acquisition) and D.2 (3-hour acquisition), showing predominantly myocardial uptake greater than that of the ribs (Perugini score of 3) and semiquantitative analysis; E) Tomographic (SPECT) images from pyrophosphate scintigraphy in two projections, showing myocardial uptake distinct from the blood pool (ventricular cavity). CMR: cardiac magnetic resonance imaging; SPECT: single-photon emission computed tomography; SSFP: steady-state free precession.*

associated with immunoglobulin light chains, and (ii) ATTR, which may be hereditary (ATTRv) or ATTRwt. This distinction is essential, as it determines both therapeutic strategies and prognosis.[4] In the current case, the slow progression of disease and its overlap with other clinical conditions delayed diagnostic confirmation — a common occurrence in clinical practice.

Besides cardiac involvement, systemic deposition of TTR — both in the variant and wild-type forms — may affect nerve fibers and lead to dysautonomia. Symptoms such as orthostatic hypotension, syncope, dizziness, vomiting, diarrhea, constipation, urinary retention, incontinence, sexual dysfunction, and other autonomic manifestations contribute to the complexity of the clinical presentation and hinder timely diagnosis.[5]

This case highlights key aspects in the evaluation of patients with suspected CA. In the past, clinical experience relied primarily on presumptive diagnoses, often made at advanced stages when classical ECG and echocardiographic findings were already evident. In most cases, the workup was limited to clinical suspicion, since imaging methods had restricted utility, genetic testing was not widely available, and biopsy was considered too invasive for a disease with no specific treatment. However, advances in diagnostic techniques and the development of targeted therapies have transformed this landscape over the past decades.[6]

Echocardiography is undoubtedly the first-line imaging test in the context of suspected CA. Speckle-tracking techniques with myocardial strain analysis are useful to differentiate CA from other causes of ventricular hypertrophy. A distinctive feature is the "apical sparing" pattern — also referred to as the "cherry on top" — characterized by reduced strain in the basal and mid-segments of the left ventricle with relative preservation of the apex. This pattern reflects the greater amyloid deposition in basal and mid-ventricular regions. A global longitudinal strain value below 13% may indicate early contractile dysfunction.[7]

CMR typically reveals abnormalities in late gadolinium enhancement sequences. Myocardial scintigraphy with technetium-labeled pyrophosphate is an excellent noninvasive diagnostic method for ATTR, with sensitivity up to 91% and specificity of 92%. Its diagnostic accuracy is based on visual assessment using the Perugini score, where grades 2 or 3 are suggestive of ATTR, and on the heart-to-contralateral hemithorax uptake ratio at 1 hour (H/CL $\geq$ 1.5).[4]

Genetic testing is essential to distinguish the different forms of CA, as prognoses and therapeutic approaches vary accordingly. Moreover, it has implications for family screening.[8] The most common ATTRv variant is Val122Ile. The true prevalence of ATTRwt, however, remains incompletely established.[9]

The treatment of ATTR aims to stabilize the TTR protein and/or suppress its hepatic production. Tafamidis is approved for the treatment of ATTR cardiomyopathy, with proven benefits in reducing mortality and hospitalizations, especially when initiated early. Other therapeutic strategies include selective TTR tetramer stabilizers (eg,

AG10), hepatic TTR synthesis inhibitors (eg, patisiran and inotersen), and the combined use of doxycycline and tauroursodeoxycholic acid. Liver transplantation, once considered an option, is now rarely performed.[4]

In conclusion, we report a case of CA in which clinical suspicion only arose after 7 years of disease progression, complicated by multiple comorbidities and limited diagnostic resources at the time. A definitive diagnosis was established only after extensive investigation, which included multimodality imaging and genetic analysis.

Author Contributions

Conception and design of the research: Yonamine MK, Pereira VC, Batista JAS, Armstrong A; acquisition of data: Yonamine MK, Aragão NJ, Pereira VC, Diniz LFB, Sasaki FM, Batista JAS, Armstrong A; analysis and interpretation of the data: Yonamine MK, Diniz LFB, Sasaki FM, Batista JAS, Armstrong A; writing of the manuscript: Yonamine MK, Batista JAS, Armstrong A; critical revision of the manuscript for intellectual content: Aragão NJ, Pereira VC, Diniz LFB, Sasaki FM, Batista JAS, Armstrong A.

Potential Conflict of Interest

No potential conflict of interest relevant to this article was reported.

Sources of Funding

There were no external funding sources for this study.

Study Association

This article is part of the final paper for Max Koki Yonamine's Medical Residency in Echocardiography at the Universidade Federal do Vale do São Francisco.

Ethics Approval and Consent to Participate

This study was approved by the Ethics Committee of the Fundação Universidade Federal do Vale do São Francisco under the protocol number 96226226.9.0000.0282. All the procedures in this study were in accordance with the 1975 Helsinki Declaration, updated in 2013. Informed consent was obtained from all participants included in the study.

Use of Artificial Intelligence

The authors did not use any artificial intelligence tools in the development of this work.

Availability of Research Data

The underlying content of the research text is contained within the manuscript.

References

1. Argon A, Nart D, Yilmazbarbet F. Cardiac Amyloidosis: Clinical Features, Pathogenesis, Diagnosis, and Treatment. Turk Patoloji Derg. 2024;40(1):1-9. doi: 10.5146/tjpath.2023.12923.
2. Kittleson MM, Maurer MS, Ambardekar AV, Bullock-Palmer RP, Chang PP, Eisen HJ, et al. Cardiac Amyloidosis: Evolving Diagnosis and Management: A Scientific Statement from the American Heart Association. Circulation. 2020;142(1):e7-e22. doi: 10.1161/CIR.0000000000000792.
3. Castano A, Haq M, Narotsky DL, Goldsmith J, Weinberg RL, Morgenstern R, et al. Multicenter Study of Planar Technetium 99m Pyrophosphate Cardiac Imaging: Predicting Survival for Patients with ATTR Cardiac Amyloidosis. JAMA Cardiol. 2016;1(8):880-9. doi: 10.1001/jamacardio.2016.2839.
4. Simões MV, Fernandes F, Marcondes-Braga FG, Scheinberg P, Correia EB, Rohde LEP, et al. Position Statement on Diagnosis and Treatment of Cardiac Amyloidosis - 2021. Arq Bras Cardiol. 2021;117(3):561-98. doi: 10.36660/abc.20210718.
5. Barroso FA, Coelho T, Dispenzieri A, Conceição I, Waddington-Cruz M, Wixner J, et al. Characteristics of Patients with Autonomic Dysfunction in the Transthyretin Amyloidosis Outcomes Survey (THAOS). Amyloid. 2022;29(3):175-83. doi: 10.1080/13506129.2022.2043270.
6. Brito D, Albrecht FC, Arenaza DP, Bart N, Better N, Carvajal-Juarez I, et al. World Heart Federation Consensus on Transthyretin Amyloidosis Cardiomyopathy (ATTR-CM). Glob Heart. 2023;18(1):59. doi: 10.5334/gh.1262.
7. Silva LLM, Vilela AA, Paladino AT Filho, Assef JE. My Approach to Echocardiography for the Diagnosis of Amyloidosis. ABC Imagem Cardiovasc. 2024;37(3):e20240056.
8. Alreshq R, Ruberg FL. Clinical Approach to Genetic Testing in Amyloid Cardiomyopathy: From Mechanism to Effective Therapies. Curr Opin Cardiol. 2021;36(3):309-17. doi: 10.1097/HCO.0000000000000841.
9. Maurer MS, Bokhari S, Damy T, Dorbala S, Drachman BM, Fontana M, et al. Expert Consensus Recommendations for the Suspicion and Diagnosis of Transthyretin Cardiac Amyloidosis. Circ Heart Fail. 2019;12(9):e006075. doi: 10.1161/CIRCHEARTFAILURE.119.006075.

This is an open-access article distributed under the terms of the Creative Commons Attribution License