

Giant Atrial Myxoma in a Pregnant Patient: A Case Report

Roberto Ramos Barbosa,¹ Caio Badiani Prando,¹ Victor Macedo Bianchini,¹ Lucas Crespo de Barros,¹ Larissa Novaes Paganini,¹ Gracielly Barros,¹ Darlan Dadalt,¹ Sergio Luis Santos Guedes,¹ Vinicius Eduardo Araújo Costa,¹ Marcus Gustavo Tito,¹ Tiago Bernardo Nery,¹ Marcio Vinicius de Nardi de Angeli,¹ Maria Eduarda Vichi Gomes Viana,¹ Mariana Oliveira Roncato,¹ João Paulo Moulin Aaad,¹ Guilherme Freitas Fernandes de Oliveira,¹ Renato Giestas Serpa,¹ Osmar Araujo Calil,¹ Luiz Fernando Machado Barbosa¹

Hospital da Santa Casa de Misericórdia de Vitória,¹ Vitória, ES – Brazil

Introduction

Atrial myxoma is the most prevalent primary heart tumor.^{1,2} Clinical manifestations of myxomas are usually nonspecific, and they may present with dyspnea, fatigue, reduced functional capacity, edema, and, eventually, cerebral embolic events with focal neurological deficits.³ Although they are classified as benign neoplasms, most commonly located in the left atrium, they can cause obstruction of intracardiac blood flow and, when friable, systemic embolism with consequent tissue ischemia.^{2,4}

In spite of higher prevalence in women (65%), diagnosis during pregnancy is considered uncommon, with greater challenges in treatment and an increased risk of fetal death.⁵ We report the case of a pregnant patient with a complication of atrial myxoma that manifested during labor.

Case report

A 28-year-old primigravida female patient, who was previously healthy, received low-risk prenatal care in the obstetrics department of a tertiary hospital. Her blood pressure was normal at all appointments, and she used multivitamins and calcium supplements. At the end of the third trimester of pregnancy, she began to report a progressive increase in dyspnea and orthopnea, associated with lower limb edema, without relieving factors.

At gestational age consistent with 37 weeks and 2 days, she was admitted to a routine-risk maternity ward linked to a tertiary hospital, reporting worsening of the symptoms mentioned during prenatal care. Fetal vitality assessment was performed using cardiotocography, which showed signs indicative of fetal compromise, mainly due to fetal bradycardia. The patient was referred to the surgical center for a cesarean section, which proceeded without complications, except for a persistent cough throughout the surgery and

bleeding in multiple tissue planes, requiring intraoperative administration of tranexamic acid.

Five hours after the procedure, she developed a seizure of unclear etiology, associated with oliguria and progressive dyspnea, requiring orotracheal intubation due to decreased level of consciousness. She also presented significant periorbital and lower limb edema. On the same day, she was referred to a secondary care hospital due to the unavailability of resources for adequate diagnosis and management at the maternity ward. The electrocardiograms performed did not show any noteworthy alterations. Transthoracic echocardiography identified the presence of a large mass in the left atrium, associated with right heart chamber overload, diffuse right ventricular hypokinesia, and pulmonary hypertension, with estimated pulmonary artery systolic pressure (PASP) of 91 mmHg. The patient was subsequently referred to a tertiary cardiology referral center and cardiac surgery due to suspected mechanical obstruction of blood flow through the mitral valve.

Following successful extubation, she underwent a new transthoracic echocardiogram, which revealed significant left atrial dilation (linear measurement of 47 mm, indexed volume of 62.2 mL/m²), with the presence of a large mobile mass in the left atrium, which projected into the mitral valve opening during diastole (Figure 1), associated with increased right ventricular dimensions (diastolic diameter of 45 mm), moderate systolic dysfunction, estimated PASP of 100 mmHg and borderline left ventricular systolic function (ejection fraction of 57%, using Simpson's method).

During hospitalization, the patient underwent surgical resection of the mobile mass identified on echocardiography. Through sternotomy and using cardiopulmonary bypass, a left atriotomy was performed with resection of the interatrial septum and identification of a 10-centimeter atrial myxoma (Figure 2) firmly adherent to the ostia of the right pulmonary veins, with a friable texture, which was resected with the right pulmonary vein and part of the left atrial wall. For complete resection, a right atriotomy with atrial septotomy was also necessary due to the extensive adherence of the myxoma. It was necessary to perform reconstruction of the interatrial septum, the left atrial wall, and the pulmonary veins, using a bovine pericardial patch. The procedure was completed without complications, and the surgical specimen was sent for histopathological analysis, which identified a myxoma measuring 10.0 × 8.6 × 3.3 cm and weighing 54 g, without associated malignant processes.

Before hospital discharge, a postoperative follow-up transthoracic echocardiogram was performed, showing a

Keywords

Myxoma; Heart Failure; Thoracic Surgery.

Mailing Address: Roberto Ramos Barbosa •

Hospital da Santa Casa de Misericórdia de Vitória. Rua Dr. João dos Santos Neves, 143. Postal code 29010-430. Vila Rubim, Vitória, ES – Brazil

E-mail: roberto.cardio@gmail.com

Manuscript received February 9, 2026, revised manuscript March 29, 2026, accepted April 29, 2026

Editor responsible for the review: Maria Otto

DOI: <https://doi.org/10.36660/abcimg.20260010>

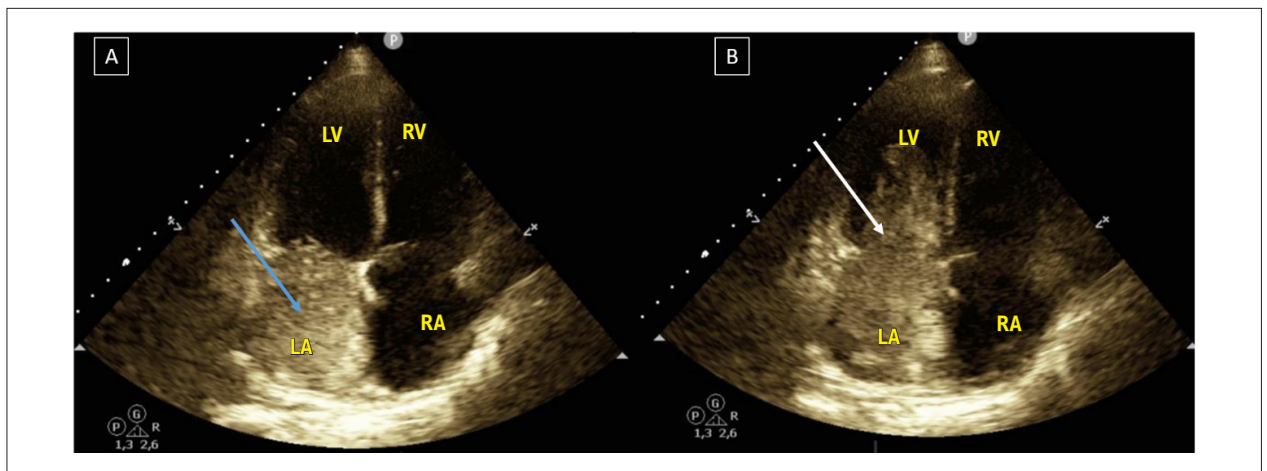


Figure 1 – Transthoracic echocardiography in apical 4-chamber view. (A) Image suggestive of a mass in the left atrium (white arrow); (B) Image of the same mass projecting into the mitral valve orifice during diastole and occupying the left ventricle (blue arrow). LA: left atrium; LV: left ventricle; RA: right atrium; RV: right ventricle.

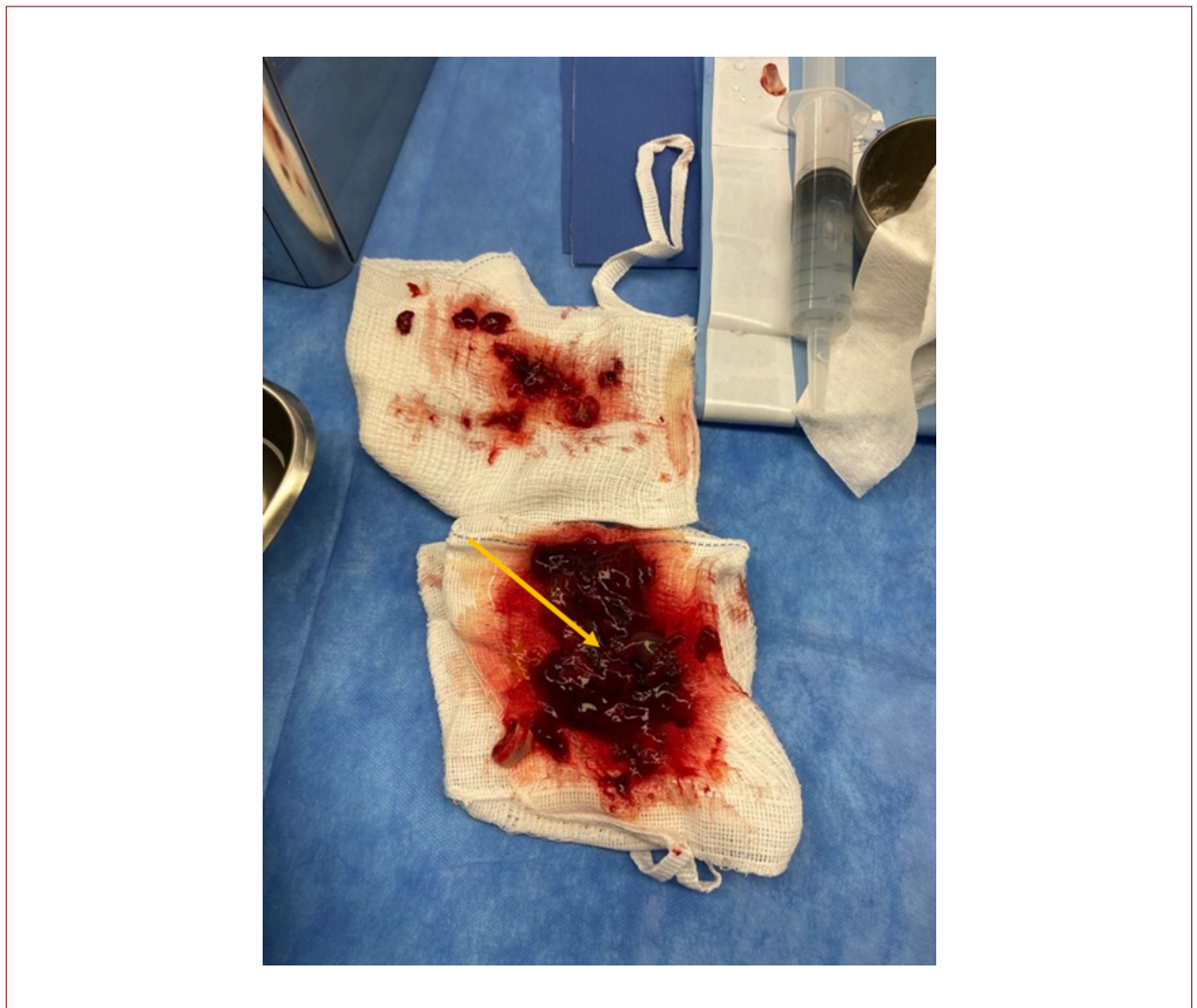

Figure 2 – Surgical specimen of the atrial myxoma (yellow arrow).

Case Report

significant reduction in PASP to 46 mmHg and preserved systolic and diastolic function in both ventricles. The patient was discharged from the hospital on the fourth postoperative day and remained asymptomatic during routine follow-up at the unit's outpatient clinic.

Discussion

Although the clinical picture is considered nonspecific, the symptoms of left atrial myxoma vary according to location, size, and mobility.^{6,7} In the reported case, the prolapse of the mass through the mitral valve orifice obstructed the left ventricular inflow tract and pulmonary venous return, raising filling pressures and triggering symptoms of cough and dyspnea, followed by acute pulmonary edema. An oligosymptomatic clinical course was likely misinterpreted as normal progression of pregnancy, with symptom exacerbation at the end of gestation and further worsening during and immediately after surgery.

The most commonly indicated treatment for clinically significant atrial myxomas is complete surgical resection, which presents excellent clinical outcomes and a low incidence of tumor recurrence, especially when accompanied by periodic echocardiographic monitoring.^{3,8,9} Various surgical techniques for left atrial myxoma resection, in addition to median sternotomy, have been described and are considered in different services, such as minimally invasive video-assisted surgery via minithoracotomy and right anterolateral minithoracotomy.⁸ However, in addition to being indicated in individualized situations, they require a higher level of specialization and availability of specific resources.

In order to ensure a complete surgical approach and better results, intraoperative transesophageal echocardiography is recommended, given that the main goals of surgery also include prevention of tumor recurrence. Risk factors associated with recurrence include incomplete resection, intracardiac implantation, embolization, and intraoperative displacement of tumor material. For this reason, a clear and comprehensive operative field should be considered, in addition to intraoperative echocardiography to confirm the absence of tumor residues.⁸

Pregnancy is a condition in which several modifications occur in the maternal organism in order to ensure optimal fetal development, such as increased cardiac output, increased blood volume, and reduced peripheral vascular resistance.¹⁰ Therefore, it is reasonable to consider whether the adaptations mentioned, especially maternal hypervolemia, may have contributed to our patient's clinical presentation. The hemodynamic changes at the end of pregnancy were added to those of the surgical trauma, culminating in a severe case of acute pulmonary edema, which required orotracheal intubation and initiated the urgent investigation of the cardiovascular abnormality.

We report a rare case of giant atrial myxoma in a pregnant patient, which manifested with typical symptoms of cardiac congestion and acute worsening after cesarean delivery, with a high risk of mortality. This highlights the importance of clinical reasoning and suspicion of possible differential

diagnoses, especially given that, from an epidemiological perspective, atrial myxoma is rare during pregnancy, which can hinder diagnosis and delay appropriate treatment.

Author contribution

Research conception and design: Barbosa RR, Prando CB, de Barros LC. Data acquisition: Prando CB, Bianchini VM, Paganini LN, de Barros GR, Dadalt D, Guedes SLS, Costa VEA, Tito MG, Nery TB, de Angeli MVN, Viana MEVG, Roncato MO, Auad JPM. Data analysis and interpretation: Barbosa RR, de Barros LC, Paganini LN, de Barros GR, Dadalt D, Auad JPM, Barbosa LFM. Manuscript writing: Barbosa RR, Prando CB, Bianchini VM. Critical review of the manuscript for important intellectual content: Barbosa RR, de Barros LC, Barbosa LFM.

Author Contributions

Conception and design of the research: Barbosa RR, Prando CB, de Barros LC; acquisition of data: Prando CB, Bianchini VM, Paganini LN, de Barros G, Dadalt D, Guedes SLS, Costa VEA, Tito MG, Nery TB, de Angeli MVN, Viana MEVG, Roncato MO, Auad JPM, Serpa RG, Calil AO; analysis and interpretation of the data: Barbosa RR, de Barros LC, Paganini LN, de Barros G, Dadalt D, Auad JPM, Barbosa LFM; writing of the manuscript: Barbosa RR, Prando CB, Bianchini VM; critical revision of the manuscript for intellectual content: Barbosa RR, de Barros LC, Barbosa LFM.

Potential Conflict of Interest

No potential conflict of interest relevant to this article was reported.

Sources of Funding

There were no external funding sources for this study.

Study Association

This study is not associated with any thesis or dissertation work.

Ethics Approval and Consent to Participate

This study received approval from the Ethics Committee of the Escola Superior de Ciências da Santa Casa de Misericórdia de Vitória (EMESCAM), under protocol number CAAE 93811125.0.0000.5065, opinion number 8.000.875. All procedures involved in this study were conducted in accordance with the 1975 Declaration of Helsinki, updated in 2013.

Use of artificial intelligence

The authors did not use any artificial intelligence tools in the development of this work.

Availability of Research Data

The underlying content of the research text is contained within the manuscript.

References

1. Li Y, Yang W, Liao S, Zuo H, Liu M. Cardiac Myxomas as Great Imitators: A Rare Case Series and Review of the Literature. *Heart Lung*. 2022;52:182-9. doi: 10.1016/j.hrtlng.2022.01.010.
2. Silva RRP, Magalhães CJ, Silva RSVD, Rocha GAF, Cavalcanti PEF, Montenegro ST. Acute ST-Elevation Myocardial Infarction in a Young Adult: Rare Presentation of Giant Atrial Myxoma. *Arq Bras Cardiol*. 2024 Apr 22;121(3):e20230538. doi: 10.36660/abc.20230538.
3. Ramcharan P, Katwaroo A, Maharaj M, Seecheran V, Lalchansingh D, Seecheran R, et al. Giant Right Atrial Myxoma Presenting with Right Heart Failure. *J Investig Med High Impact Case Rep*. 2025;13:23247096251329706. doi: 10.1177/23247096251329706.
4. Marta L, Peres M, Alves M, Silva GF. Giant Left Atrial Myxoma Presenting as Acute Myocardial Infarction. *Rev Port Cardiol*. 2012;31(12):815-9. doi: 10.1016/j.repc.2012.04.013.
5. John AS, Connolly HM, Schaff HV, Klarich K. Management of Cardiac Myxoma during Pregnancy: A Case Series and Review of the Literature. *Int J Cardiol*. 2012;155(2):177-80. doi: 10.1016/j.ijcard.2011.05.069.
6. Xue XS, Liang JY, Bao SJ, Ma HF, Zhan B, Liu Y. Cardiac Myxoma: A Report of Two Cases and Review of the Literature. *Radiol Case Rep*. 2025;21(1):407-13. doi: 10.1016/j.radcr.2025.09.085.
7. Okongwu CC, Olaofe OO. Cardiac Myxoma: A Comprehensive Review. *J Cardiothorac Surg*. 2025;20(1):151. doi: 10.1186/s13019-024-03333-2.
8. Kavakli AS, Ozturk NK. Determination of Residual Mass in Left Ventricle by Intraoperative Transesophageal Echocardiography after a Giant and Floating Left Atrial Myxoma Resection. *Braz J Anesthesiol*. 2018;68(5):524-7. doi: 10.1016/j.bjan.2017.10.001.
9. Hernandez N, DiLeo M, Wong CK, Alam M. Sequelae and Surgical Management of Giant Cardiac Myxoma. *Tex Heart Inst J*. 2025;52(1):e248413. doi: 10.14503/THIJ-24-8413.
10. Avila WS, Alexandre ERG, Castro ML, Lucena AJG, Marques-Santos C, Freire CMV, et al. Brazilian Cardiology Society Statement for Management of Pregnancy and Family Planning in Women with Heart Disease - 2020. *Arq Bras Cardiol*. 2020;114(5):849-942. doi: 10.36660/abc.20200406.



This is an open-access article distributed under the terms of the Creative Commons Attribution License